

HAND/PERIPHERAL NERVE

Enhancing the Outcome of Traumatic Sensory Nerve Lesions of the Hand by Additional Use of a Chitosan Nerve Tube in Primary Nerve Repair: A Randomized Controlled Bicentric Trial

Florian Neubrech, M.D.

Michael Sauerbier, M.D.

Wibke Moll, M.D.

Jessica Seegmüller, M.D.

Sina Heider, M.D.

Leila Harhaus, M.D.

Berthold Bickert, M.D.

Ulrich Kneser, M.D.

Thomas Kremer, M.D.

AQ1

Ludwigshafen and Frankfurt am Main,
Germany



Quality of Care



Background: Peripheral sensory nerve injuries present a significant yet common challenge in acute hand trauma surgery. Standard treatment remains microsurgical end-to-end nerve repair where appropriate. Permanent loss of sensitivity and painful neuroma formation are typical sequelae of unsuccessful surgery. The objective of this study was to evaluate whether the additional use of a chitosan nerve tube in primary nerve repair positively influences sensory recovery.

Methods: A randomized, controlled, two-center trial with parallel group design and double-blind assessment was conducted to demonstrate the superiority of the additional use of a chitosan nerve tube compared with microsurgical nerve repair alone. Seventy-four participants were enrolled. The primary outcome parameter used was degree of static two-point discrimination at 6 months after surgery. Additional secondary outcome parameters included filament recognition testing (Semmes-Weinstein); pain; neuroma development; and the Disabilities of the Arm, Shoulder and Hand score.

Results: Nerve repair with additional use of chitosan nerve tubes (intervention group) significantly increased both tactile gnosis (expressed by two-point discrimination) and sensitivity (expressed by Semmes-Weinstein testing). The mean two-point discrimination at 6-month follow-up was 8 mm (range, 2 to 20 mm) in the control group and 6.3 mm (range, 1 to 15 mm) in the intervention group, respectively ($p = 0.029$). Two-point discrimination correlated with the Disabilities of the Arm, Shoulder and Hand score. In the control and intervention groups, respectively, three versus zero neuromas were found.

Conclusions: Peripheral sensory nerve regeneration can be improved significantly by additional use of a chitosan nerve tube. An improved ability of static two-point discrimination is clinically relevant. (*Plast. Reconstr. Surg.* 142: 00, 2018.)

CLINICAL QUESTION/LEVEL OF EVIDENCE: Therapeutic, I.

Peripheral nerve injuries are frequent and grave concomitant injuries in acute hand and upper extremity trauma.¹ Severed nerves do not heal spontaneously. The integrity

of the epineural sheath has to be repaired using microsurgical techniques. The standard treatment for nerve lesions without a defect is end-to-end suture, whereas the gold standard treatment for

From the Department of Hand, Plastic and Reconstructive Surgery—Burn Center, BG Trauma Center Ludwigshafen; and the Department for Plastic, Hand and Reconstructive Surgery, BG Trauma Center Frankfurt am Main.

Received for publication October 7, 2017; accepted February 9, 2018.

This trial is registered under the name "Chitosan Nerve Tube for Primary Repair of Traumatic Sensory Nerve Lesions of the Hand (CNT)," ClinicalTrials.gov identification number NCT02372669 (<https://clinicaltrials.gov/ct2/show/NCT02372669>).

Copyright © 2018 by the American Society of Plastic Surgeons

DOI: 10.1097/PRS.0000000000004574

Disclosure: Trial was sponsored by Medovent. Medovent manufactures the chitosan nerve tube that was used in this trial. Implants were provided by Medovent free of charge. The study was conceived and designed prior to seeking financial support. With respect to this study, Medovent was excluded from any aspect of design, conduct, analysis, write-up or publication of the trial. None of the authors have any personal financial ties to Medovent. None of the authors has received reimbursements, fees, funding, or salary from Medovent. None of the authors hold any stocks or shares.

AQ5

nerve gaps is the use of autologous nerve grafts.² Despite these measures, standard treatment may often result in poor nerve regeneration. Approximately one-third of patients do not regain significant sensitivity of injured fingers, resulting in impaired whole hand function.³ A further postoperative complication of nerve repair is excessive and untargeted axonal growth resulting in painful neuroma. Corresponding patients typically suffer from persistent pain for years.^{4–6} Furthermore, patients requiring autologous nerve grafting may experience moderate but significant donor-site morbidity, resulting from sensory nerve removal from another body region.⁷

In summary, alternative and additional treatment options for peripheral nerve repair are desirable. One promising option with which to overcome the problems of the current standard treatment may be nerve tubes. Today, these are small, biosynthetic, resorbable tubes that can bridge nerve gaps, protect the nerve suture from scar formation, and guide growing axons.⁸ Besides their mechanical effects, modern nerve tubes have a semipermeable barrier that conditions the enrichment of oxygen, proteins, and growth factors in the lumen, supporting nerve regeneration by reinforcing the mechanisms of Schwann cells.⁹ Available nerve tubes consist of different biomaterials. Chitosan, a derivative of chitin, seems to be especially promising because it provides inherent bioactive effects. In experimental studies, chitosan was shown to have positive effects on the survival and orientation of Schwann cells¹⁰ and on the survival and differentiation of neuronal cells^{11,12} and to prevent neuroma formation.¹³ Chitosan has a positive surface charge that can be technically modified by N-acetylation.¹² In theory, the positive charge interacts with the surface charge of axons and guides them through the tube. Controlled growth of axons could prevent neuroma formation.

There are two clinical indications for the use of nerve tubes. One is bridging of a short nerve defect as an alternative to autologous nerve grafting. The other option is to apply nerve tubes in addition to primary nerve repair to coat and guard a nerve suture. Nerve tube use as a good alternative to nerve grafting in sensory nerve defects smaller than 3 cm has been well supported in the literature.¹⁴ However, evidence supporting the additional use of nerve tubes for primary nerve sutures is still lacking. Theoretically, the additional use of a nerve tube allows optimal tension-free primary nerve suture, as a minimal gap can be accepted, in contrast to primary suture alone.

This represents a major advantage, as tension prohibits the healing process substantially in repaired nerves.¹⁵ Nerve healing may be further supported by the biological effects of nerve tubes and of chitosan in general. The objective of this study was to evaluate whether the additional use of a chitosan nerve tube in primary repair of traumatic sensory nerve lesions of the hand without a gap influences the sensory convalescence or not.

PATIENTS AND METHODS

Study Design and Setting

A randomized, controlled, two-center trial with a parallel group design and double-blind assessment was conducted to show the superiority of the additional use of a chitosan nerve tube in primary nerve repair. Between March of 2015 and June of 2017, 74 participants were enrolled in two centers: BG Trauma Center Ludwigshafen (Ludwigshafen, Germany) and BG Trauma Center Frankfurt am Main (Frankfurt am Main, Germany). Both centers are certified hand trauma centers of the Federation of European Societies for Surgery of the Hand.

The study was registered at ClinicalTrials.gov (identification number NCT02372669), and the study protocol was published by the authors before the study was conducted¹⁶ and was approved by the Ethics Committee of Rhineland-Palatinate, Mainz, Germany [reference number 837.380.14 (9619)]. Prospective written informed consent was obtained from all enrolled participants.

Participants and Randomization

All individuals with clinical signs of sensory nerve lesions of the hand were consecutively screened for eligibility during the study period. There was a preoperative and an intraoperative survey. After the individual was found to be eligible by checking the preoperative and intraoperative inclusion and exclusion criteria (see below), participants were randomized in a 1:1 ratio by alternating lists to the control group or the intervention group. If more than one nerve was injured, all nerves of one individual were treated in the same fashion.

Preoperative Inclusion Criteria

Preoperative inclusion criteria included the following: lesion between the distal carpal tunnel and the distal finger joint, complete loss of a nerve-specific receptive field of the finger, age between 18 and 67 years, trauma not older than 72 hours, and signed informed consent.

Volume 142, Number 2 • Chitosan Tubes in Primary Nerve Repair

Preoperative Exclusion Criteria

Preoperative exclusion criteria included the following: amputated or avascular fingers, infection of the wound, known preexisting impaired sensitivity, pregnancy, known immunodeficiency, and participation in other trials.

Intraoperative Inclusion Criteria

Intraoperative inclusion criteria included verification of a sensory nerve lesion without a gap and presence of a nerve that could be sutured in end-to-end fashion.

Intraoperative Exclusion Criteria

Intraoperative exclusion criteria included avascular fingers and multiple nerve lesions that could not be randomized uniformly. Basic data for analysis included age, sex, localization of injury (e.g., distance from lesion to finger pulp), and concomitant arterial injuries.

Interventions

Nerve lesions of individuals that were allocated to the control group were treated by epineural end-to-end suture, using a 9-0 United States Pharmacopoeia microsuture and a surgical microscope (active comparator). In the intervention group, before performing the end-to-end suture, a chitosan nerve tube (Reaxon; Medovent, Mainz, Germany) was imposed on one side of the severed nerve. Then, end-to-end suture was performed in the same way as in control group. Finally, the nerve tube (10 mm in length, 2.1 mm in diameter) was positioned at the site of the suture centrally and fixed with a single stitch of the same suture material on each side. The chitosan-based nerve tube used is a U.S. Food and Drug Administration–approved medical product.

Postoperatively, antibiotics (usually cefuroxime for 5 days, various manufacturers) were used. Type and duration of splinting conformed with the concomitant injuries and was used only if there were fractures or tendon injuries.

Follow-Up and Blinding

Follow-up examinations were performed at 3, 6, and 12 months after surgery. The endpoint for analysis of the primary outcome parameter and the determinant for sample size planning were derived from 6-month data; thus, the trial was stopped after completion of 6-month data. Data of individuals that had also completed the 12-month follow-up at that time are also reported.

The degree of static two-point discrimination after 6 months was the primary outcome parameter. Static two-point discrimination was measured using a double-tip compass (NCD Medical/

Prestige, Los Angeles, Calif.). Testing was performed on the radial or ulnar finger pulp halves with preoperatively failed nerve-specific receptive fields and on the correlating contralateral side. The measure points were applied in the longitudinal direction. The application pressure was defined by self-weight of the compass (10 g). Dynamic testing of two-point discrimination was not performed.

Secondary outcome parameters were sensitivity measured by the Semmes-Weinstein method¹⁷; self-report of pain on visual analogue scales ranged from 0 to 10¹⁸; the Disabilities of the Arm, Shoulder and Hand score in its validated German version¹⁹; finger mobility measured as mean fingertip-to-palm distance; and grip strength measured with a Jamar dynamometer on level 2 (Sammons Preston, Inc., Bolinbrook, Ill.). In addition, adverse events and any type of revision surgery were recorded during hospitalization and retrospectively in the follow-ups. Appearance of neuroma was assessed clinically by local electrifying pain in percussion (Tinel test). Detection of neuroma by sonography was planned but was not applicable in favor of blinding (for details, see below).

Intervention type was blinded for the participant because of informed consent and institutional arrangement. Follow-up examinations were performed by blinded independent investigators.

Pretrial and Sample Size

A retrospective pretrial was performed in preparation for this study to gain assumptions for the mean value of two-point discrimination and its standard deviation.²⁰ Thirty-seven individuals per group were calculated to be necessary to show superiority using a two-sided *t* test with an alpha level of 5 percent and a power of 80 percent. The statistical analysis plan scheduled a per-protocol analysis.

Statistical Analysis

GraphPad Prism V5.0 (GraphPad Software, Inc., La Jolla, Calif.) software was used for analysis and drawing. Two-tailed *t* test was performed. The chi-square test for trends and Fisher's exact test for dichotomous traits were used for the nonparametric methods. Pearson correlation coefficients were calculated for paired observations. Findings were regarded as significant for values of $p < 0.05$.

RESULTS**Basic Data**

The study period was between March of 2015 and June of 2017, ceasing on reaching 74 (2×37) analyzable participants with complete 6-month data. Seventy-eight of 100 screened participants



CONSORT 2010 Flow Diagram

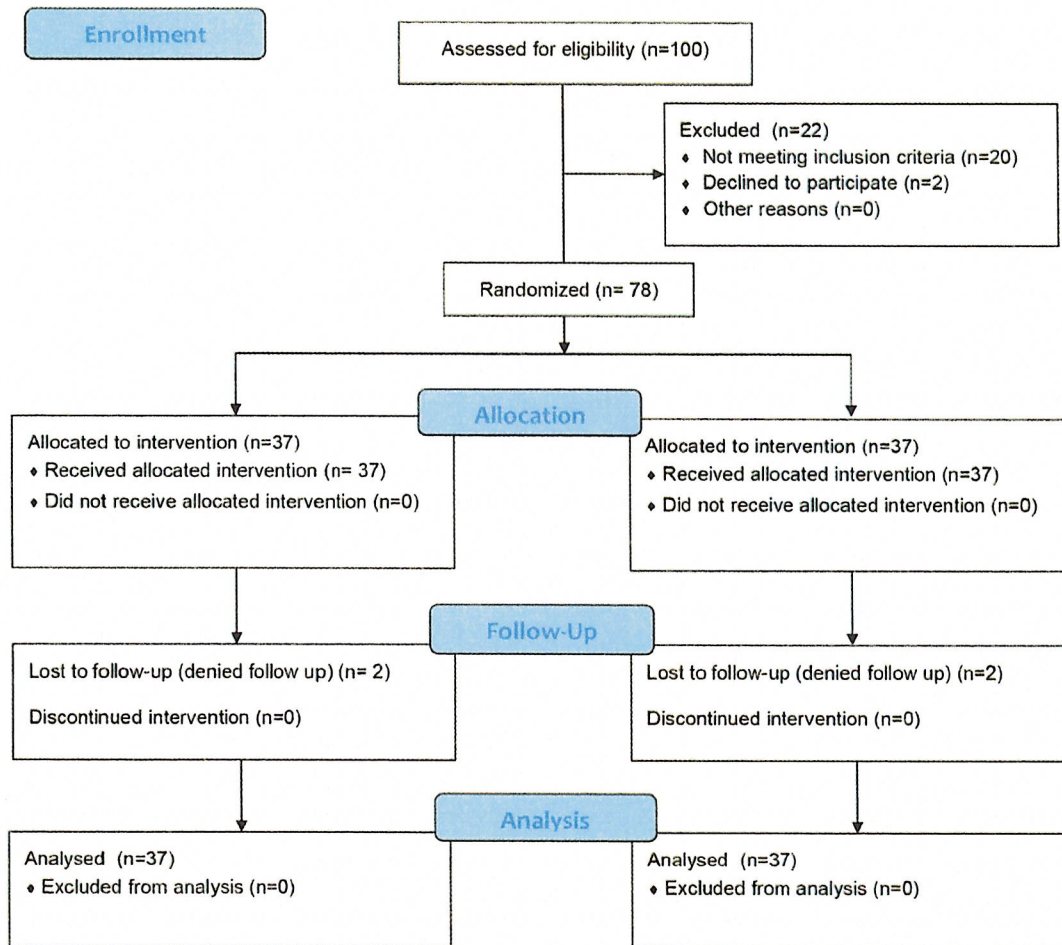


Fig. 1. Study flow diagram according to Consolidated Standards of Reporting Trials (CONSORT) 2010 guidelines.

FI were eligible to be enrolled in the study. Four participants were lost to follow-up, withdrawing from the study without cause. Figure 1 shows the study flow diagram according to Consolidated Standards of Reporting Trials 2010 guidelines. Sixty and 14 of the analyzed individuals were recruited in the study centers of Ludwigshafen and Frankfurt, respectively. These 74 participants (55 men and 19 women), with an average age of 43 years (range, 19 to 67 years), were distributed equally (37 individuals each) in the intervention

and control groups. The trial consisted of 74 participants with a total of 79 nerve injuries. In the intervention group, 41 nerves were injured in 37 participants; in the control group, 38 nerves were injured in 37 participants. Analyses did not reveal any significant differences between the groups regarding age, sex, localization of injury, or concomitant arterial injuries (Fig. 2). Mean distance from lesion to finger pulp was 46.6 mm (range, 12 to 95 mm) in the control group and 46.0 mm (range, 10 to 110 mm) in the intervention group.

F2

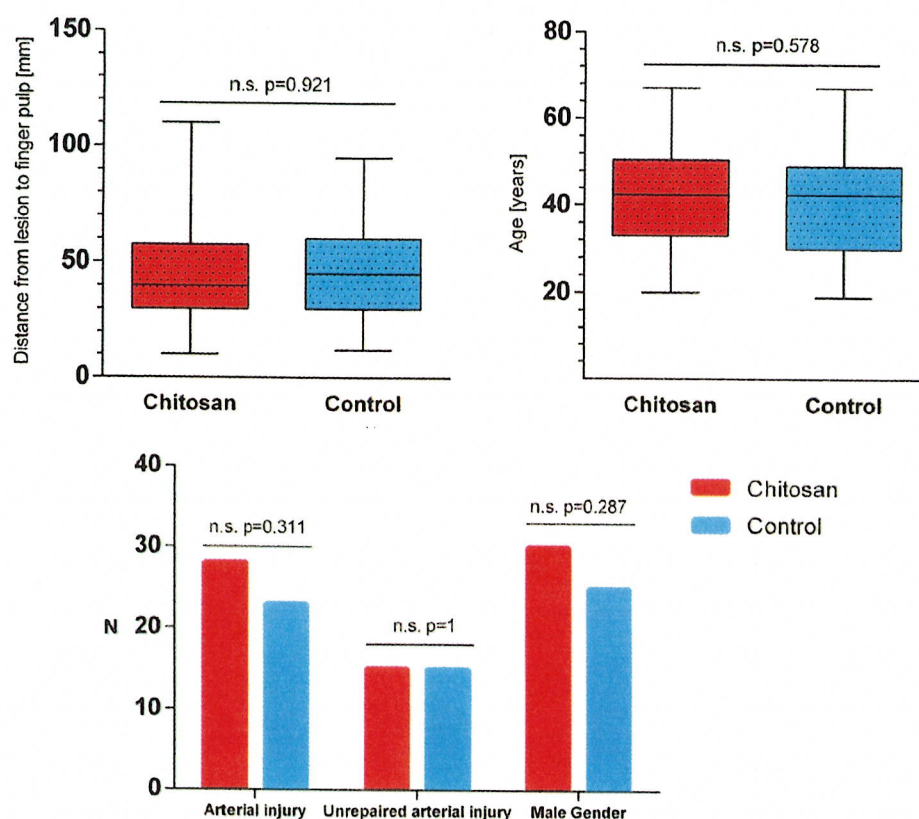


Fig. 2. Allocation of potential confounding variables. (Above, left) Location of injury as the distance from the nerve lesion to the finger pulp. (Above, right) Age. (Below) Concomitant arterial injuries/sex. (Above) Data are shown in box plots (bars = minimum to maximum). (Below) Data are shown in histogram with totals (n.s., not significant).

Sensory Recovery

The average static two-point discrimination 3 months after surgery was 11 mm (range, 5 to 25 mm) in the control group and 11.4 mm (range, 4 to 20 mm) in the intervention group. Differences in healing process became apparent after 6 months. The mean two-point discrimination was 8 mm (range, 2 to 20 mm) and 6.3 mm (range, 1 to 15 mm) in the control and intervention groups, respectively. This result was significant regarding the primary outcome parameter ($p = 0.029$). Two-point discrimination of the uninjured contralateral side was exemplarily measured at 6-month follow-up. Two-point discrimination of all uninjured sides was 2.68 mm (range, 1 to 7 mm) and the same in the contralateral side of the analyzed groups. At study closure, 20 individuals with 22 injured nerves in the intervention group and 17 control patients with 19 injured nerves were also examined for a follow-up after 12 months. At this examination, mean two-point discrimination was 8 mm (range, 3 to 20 mm) in the control group and 5.5 mm (range, 1 to 5 mm) in the intervention group. This result

would have been mathematically significant in an isolated consideration if the study had been powered for this analytical approach. Figure 3 displays the recovery of two-point discrimination over time. F3

On Semmes-Weinstein testing at 6-month follow-up, more individuals in the intervention group were able to recognize the thinner filaments (filaments 4 and 5) compared with individuals in the control group. This was a significant result regarding the trend of recognized filament classes ($p = 0.019$) (Fig. 4). F4

Secondary Endpoints

Neuroma

Clinical evidence for neuroma was found in three nerves of three subjects (8 percent) in the control group and in none of the interventional cases. This difference was not statistically significant. Table 1 shows data as a fourfold table. The initially planned sonographic detection of neuroma failed because the tubes could still be seen on sonography 3 months postoperatively, which would have compromised blinded assessment. Therefore,

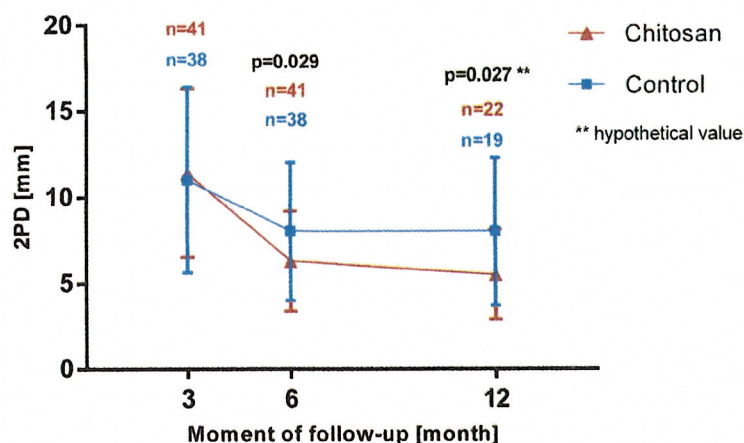


Fig. 3. Static two-point discrimination (2PD) over time. Bars = standard deviation (*n*, number of nerves). At 3-month and 6-month follow-up, 37 individuals were examined in each group. At 12-month follow-up, 20 individuals were examined in the intervention group (with additional use of a chitosan nerve tube) and 17 individuals were examined in the control group.

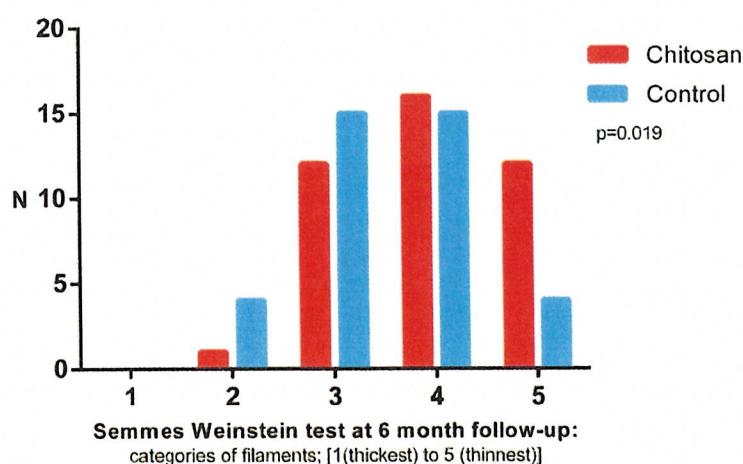


Fig. 4. Semmes-Weinstein test. Number of individuals that could recognize filaments of different caliber. For each individual, the thinnest perceptible filament is represented once in the histogram.

Table 1. Clinical Appearance of Neuroma at 6-Month Follow-Up

	Chitosan	Control	Total No. of Subjects
Neuroma	0	3	3
No neuroma	37	34	71
Total no. of subjects	37	37	NS*

NS, not significant.
**p* = 0.239.

the procedure was stopped after examination of the first subject of the intervention group.

Pain

Chronic pain was rare in both groups. On average, after 6 months, global pain was rated

on a visual analogue scale from 0 to 10, with 1.3 (range, 0 to 8) in the control group and 1 (range, 0 to 7) in intervention group (Fig. 5).

F5

Complications and Unintended Effects

Initial surgery was performed without any complication in all of the cases. There were no implant-associated complications. At the endpoint of 6-month follow-up, two major complications were registered in the control group. One individual had developed a persistent complex regional pain syndrome and the other had a wound healing disturbance requiring revision surgery (arthrodesis of a distal finger joint) that was performed 3 weeks after initial treatment. Wounds

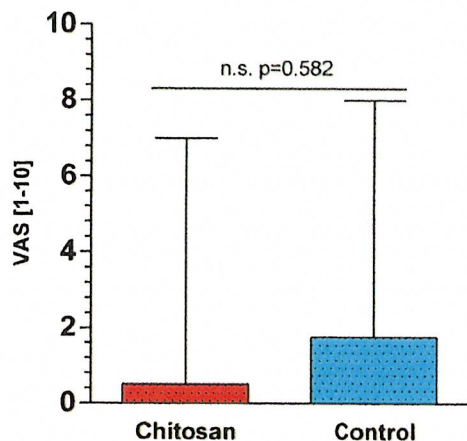


Fig. 5. Chronic global pain at 6-month follow-up. Data are shown in box plots. Bars = minimum to maximum. VAS, visual analogue scale (range, 0 to 10); *n.s.*, not significant.

healed uneventfully after revision surgery. There were no postoperative complications recorded in the intervention group. The use of a nerve tube did not decrease finger mobility (Fig. 6).

Disabilities of the Arm, Shoulder and Hand Score; Finger Mobility; and Grip Strength

At 6-month follow-up, the average Disabilities of the Arm, Shoulder and Hand score was 11.3 (range, 0 to 60) in the control group and 9.1 (range, 0 to 47) in the intervention group. Finger mobility, expressed as mean fingertip-to-palm distance, was 0.8 cm (range, 0 to 6 cm) in the control group and 0.5 cm (range, 0 to 6 cm) in the intervention group. Average grip strength of the injured hands was 33.4 kg (range, 8 to 54 kg) in the control group and 33.2 kg (range, 8 to 48 kg) in the intervention group. Correlation analysis did reveal a moderate correlation between the ability of two-point discrimination and Disabilities of the Arm, Shoulder and Hand score; a weak correlation between two-point discrimination and finger mobility; and no correlation between two-point discrimination and grip strength. Regression line between two-point discrimination and Disabilities of the Arm, Shoulder and Hand score differed significantly from 0 ($p = 0.002$), whereas the other regression analysis did not (Fig. 7).

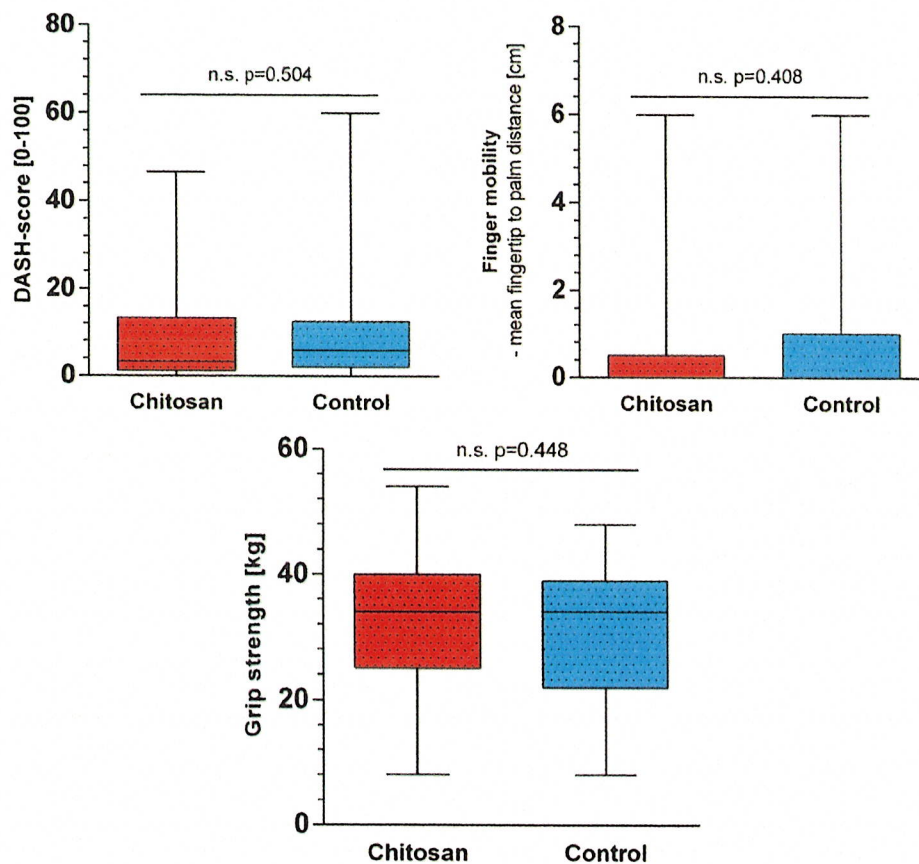


Fig. 6. Secondary endpoints at 6-month follow-up. (Above, left) Disabilities of the Arm, Shoulder and Hand (DASH) score. (Above, right) Finger mobility as mean fingertip-to-palm distance. (Below) Grip strength of the injured hand. Data are shown in box plots. Bars = minimum to maximum (*n.s.*, not significant).

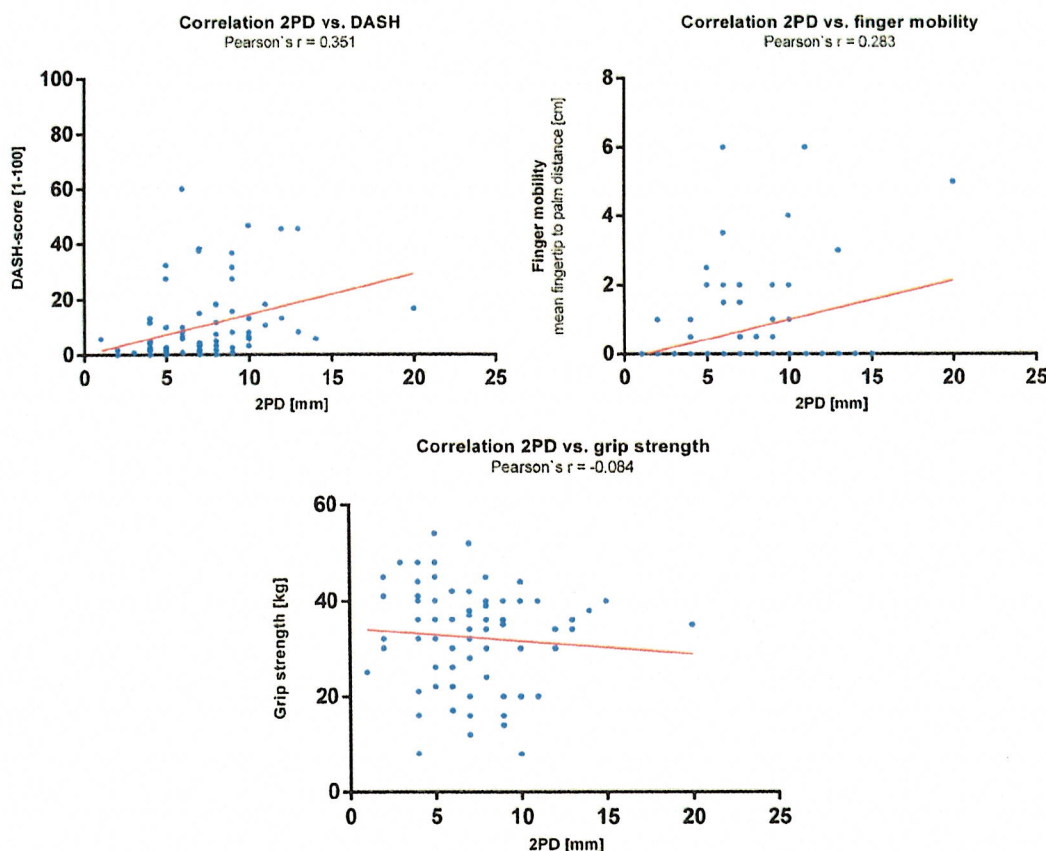


Fig. 7. Correlation analysis. Shown are correlation analysis between two-point discrimination (2PD) and (above, left) Disabilities of the Arm, Shoulder and Hand (DASH) questionnaire score; (above, right) finger mobility as mean fingertip-to-palm distance; and (below) grip strength. Blue points represent single value pairs, and red lines represent linear regression curves.

DISCUSSION

The current study supports previous comparable series¹⁴ showing that the use of nerve tubes can lead to excellent results. As may be expected, the additional application of nerve tubes for primary nerve repair results in improved outcomes compared with nerve reconstruction using nerve tubes for gaps.¹⁴ Compared with the literature, the ability of static two-point discrimination with additional use of nerve tubes was also better than the results for digital nerve repair alone.^{21,22} To the authors' knowledge, the current study represents the first prospective randomized trial in the literature demonstrating superior outcomes of the additional use of a chitosan nerve tube in direct comparison with nerve repair alone.

Strictly speaking, our findings apply only to digital nerve lesions. These were chosen because they are ideal for clinical research on peripheral nerve repair, because required follow-up intervals are shorter compared with mixed and motor nerves, and the ability of two-point discrimination

can be precisely assigned to the injured nerve at follow-up examinations.²³ Furthermore, two-point discrimination can be measured with a level of data that allow parametric and nonparametric calculations. In addition, our study proved that the two-point discrimination is a good endpoint parameter for nerve repair studies, because two-point discrimination directly impacts the Disabilities of the Arm, Shoulder and Hand score and thus activities of daily living. Restrictively, it must be emphasized that two-point discrimination does not express all qualities of nerve recovery. For example, the recognition of complex shapes was not tested. This limitation was attributable to the standardization of parameters for a clinical research trial.

In peripheral nerve recovery of finger nerves, the effect of contralateral nerve sprouting must be considered. In this study, the effect was addressed using a control group. An influence of immobilization on nerve recovery cannot be excluded in general, even though there is a complete lack of

Volume 142, Number 2 • Chitosan Tubes in Primary Nerve Repair

data on this question. The distance from lesion to finger pulp was balanced between the groups.

In the current trial, the additional use of chitosan nerve tubes improved sensory convalescence of digital nerves with regard to both sensitivity (Semmes-Weinstein test) and tactile gnosis (two-point discrimination). In this context, sensitivity means the ability to recognize cutaneous pressure thresholds and reflects pure reinnervation. The concept of tactile gnosis adds a central processing of stimuli and thereby the ability to recognize objects and is a marker of functional nerve recovery.²¹ Dynamic methods of testing were also taken into consideration but were not performed in favor of standardization.

Direct tension-free microsurgical repair remains the gold standard therapy for nerve injuries.² Because of the findings of this study, the authors recommend the additional use of nerve tubes in primary nerve repair. Of course, our study did not compare chitosan nerve tubes to nerve tubes made of other biomaterials. This would require direct comparisons in future trials. In contrast, there are experimental data showing biological effects of chitosan on nerve cells and Schwann cells that could make it the ideal choice for the construction of nerve tubes.¹⁰⁻¹³

In this trial, there was a clear but statistically nonsignificant trend in reduction of neuroma through application of a chitosan nerve tube. However, the study failed to prove a benefit in neuroma reduction through a chitosan nerve tube. We postulate that the sample size was insufficient to show such significant benefits in digital nerve repair. In the planning study of this trial, neuroma was rarely seen in digital nerve repair but was clinically verified in up to 80 percent of cases after injury of forearm nerves.²⁰ The positive results of our study regarding neuroma formation could be transferred to more proximal nerve lesions and could be the subject of future investigations.

The 12-month findings of this trial are preliminary, in contrast to the 6-month results. Beforehand, it was determined that the study should prove superiority after 6 months. Therefore, to be methodically precise, the trial was stopped after accrual of 6-month data.

Some shortcomings of the trial are attributable to the conditions of emergency surgery. Alternate randomization is more like a quasi-randomization method. An external block randomization would have been desirable but could not be realized in the acute trauma setting. However, the procedure guaranteed an equal distribution of the only certain interfering variable (i.e., level of trauma)¹⁴ and

of the most discussed interfering variables (i.e., age, sex, and arterial injury).^{14,22,25,26} The anticipated participant recruitment ratio between the two trauma centers was unlikely following the pre-trial results. Another desirable feature of the trial would have been confirmatory methods for neuro-mas that were only detected clinically. Sonography was not applicable in favor of blinding. It remains unclear how long it takes for the chitosan nerve tube to be undetectable by ultrasound; therefore, this objective method could not be applied.

CONCLUSIONS

Through its Disabilities of the Arm, Shoulder and Hand score impact, the ability of static two-point discrimination is of clinical relevance. We conclude that peripheral sensory nerve regeneration, measured both by tactile gnosis and sensitivity, can be improved significantly by additional use of chitosan nerve tubes.

Florian Neubrech, M.D.

BG Trauma Center Ludwigshafen
Ludwig-Guttmann-Strasse 13
D-67071 Ludwigshafen, Germany
floneb@gmx.de

ACKNOWLEDGMENT

The authors thank Hischam Taha, M.R.C.S., F.R.C.S., for proofreading and for the linguistic revision of their article.

REFERENCES

- Scholz T, Krichovsky A, Sumarto A, et al. Peripheral nerve injuries: An international survey of current treatments and future perspectives. *J Reconstr Microsurg*. 2009;25:339-344.
- Konofaos P, Ver Halen JP. Nerve repair by means of tubulization: Past, present, future. *J Reconstr Microsurg*. 2013;29:149-164.
- Chaise F, Friol JP, Gaisne E. Results of emergency repair of wounds of palmar collateral nerves of the fingers (in French). *Rev Chir Orthop Reparatrice Appar Mot*. 1993;79:393-397.
- Lewin-Kowalik J, Marcol W, Kotulska K, Manderka M, Klimczak A. Prevention and management of painful neuroma. *Neurol Med Chir (Tokyo)* 2006;46:62-67; discussion 67-68.
- Zimmermann M. Pathobiology of neuropathic pain. *Eur J Pharmacol*. 2001;429:23-37.
- Bowsher D. Human "autotomy". *Pain* 2002;95:187-189.
- Hallgren A, Björkman A, Chemnitz A, Dahlin LB. Subjective outcome related to donor site morbidity after sural nerve graft harvesting: A survey in 41 patients. *BMC Surg*. 2013;13:39.
- Ijpma FF, Van De Graaf RC, Meek MF. The early history of tubulation in nerve repair. *J Hand Surg Eur Vol*. 2008;33:581-586.
- Daly W, Yao L, Zeugolis D, Windebank A, Pandit A. A biomaterials approach to peripheral nerve regeneration: Bridging the peripheral nerve gap and enhancing functional recovery. *J R Soc Interface* 2012;9:202-221.

10. Yuan Y, Zhang P, Yang Y, Wang X, Gu X. The interaction of Schwann cells with chitosan membranes and fibers in vitro. *Biomaterials* 2001;25:1273-1278.
11. Simões MJ, Gärtner A, Shirosaki Y, et al. In vitro and in vivo chitosan membranes testing for peripheral nerve reconstruction. *Acta Med Port*. 2011;24:43-52.
12. Freier T, Koh HS, Kazazian K, Shoichet MS. Controlling cell adhesion and degradation of chitosan films by N-acetylation. *Biomaterials* 2005;26:5872-5878.
13. Marcol W, Larysz-Brysz M, Kucharska M, et al. Reduction of post-traumatic neuroma and epineural scar formation in rat sciatic nerve by application of microcrystalline chitosan. *Microsurgery* 2011;31:642-649.
14. Meek MF, Coert JH. Recovery of two-point discrimination function after digital nerve repair in the hand using resorbable FDA- and CE-approved nerve conduits. *J Plast Reconstr Aesthet Surg*. 2013;66:1307-1315.
15. Lundborg G, Dahlin L, Danielsen N, Zhao Q. Trophism, tropism, and specificity in nerve regeneration. *J Reconstr Microsurg*. 1994;10:345-354.
16. Neubrech F, Heider S, Harhaus L, Bickert B, Kneser U, Kremer T. Chitosan nerve tube for primary repair of traumatic sensory nerve lesions of the hand without a gap: Study protocol for a randomized controlled trial. *Trials* 2016;17:48.
17. Weinstein S. Fifty years of somatosensory research: From the Semmes-Weinstein monofilaments to the Weinstein Enhanced Sensory Test. *J Hand Ther*. 1993;6:11-22; discussion 50.
18. Scott J, Huskisson EC. Vertical or horizontal visual analogue scales. *Ann Rheum Dis*. 1979;38:560.
19. Germann G, Harth A, Wind G, Demir E. Standardisation and validation of the German version 2.0 of the Disability of Arm, Shoulder, Hand (DASH) questionnaire (in German). *Unfallchirurg* 2003;106:13-19.
20. Neubrech F, Heider S, Otte M, Hirche C, Kneser U, Kremer T. Nerve tubes for the repair of traumatic sensory nerve lesions of the hand: Review and planning study for a randomised controlled multicentre trial (in German). *Handchir Mikrochir Plast Chir*. 2016;48:148-154.
21. Goldie BS, Coates CJ, Birch R. The long term result of digital nerve repair in no-man's land. *J Hand Surg Br*. 1992;17:75-77.
22. al-Ghazal SK, McKiernan M, Khan K, McCann J. Results of clinical assessment after primary digital nerve repair. *J Hand Surg Br*. 1994;19:255-257.
23. Lohmeyer JA, Kern Y, Schmauss D, et al. Prospective clinical study on digital nerve repair with collagen nerve conduits and review of literature. *J Reconstr Microsurg*. 2014;30:227-234.
24. Wang Y, Sunitha M, Chung KC. How to measure outcomes of peripheral nerve surgery. *Hand Clin*. 2013;29:349-361.
25. Mackinnon SE. Technical use of synthetic conduits for nerve repair. *J Hand Surg Am*. 2011;36:183.
26. Weinzwieg N, Chin G, Mead M, et al. Recovery of sensibility after digital neurotaphy: A clinical investigation of prognostic factors. *Ann Plast Surg*. 2000;44:610-617.

AQ4

AUTHOR QUERIES

AUTHOR PLEASE ANSWER ALL QUERIES

- AQ1—For indexing purposes, please confirm that author names have been correctly identified as given names (blue), surnames (red), and suffixes (black). Color in the byline will not appear on the final published version.
- AQ2—Sentence OK as edited (“localization of injury (e.g., distance from lesion to finger pulp)”? If not, please revise as needed.
- AQ3—OK to cite reference 26 here (“injury”.14,22,25,26”) ? If not, please cite in the correct place, renumbering as needed throughout and in reference list so that refs are cited in numerical order, per Journal style.
- AQ4—Note to CE: Please check the citation for that reference
- AQ5—Please double-check the financial disclosure statement to confirm that it is correct. If it is incorrect, please revise as needed.